



ERCP performed through previously placed duodenal stents: a multicenter retrospective study of outcomes and adverse events

Judith Staub, MD,¹ Ali Siddiqui, MD,² Linda Jo Taylor, BS,¹ David Loren, MD,² Tom Kowalski, MD,² Douglas G. Adler, MD¹

Salt Lake City, Utah; Philadelphia, Pennsylvania, USA

Background and Aims: ERCP performed through previously placed enteral stents is an uncommon procedure without a significant amount of supporting literature and with a wide reported range of technical success. The purpose of this study was to evaluate and better define the technical feasibility and safety of performing ERCP through enteral stents in patients with combined malignant biliary and gastric outlet obstruction.

Methods: We conducted a multicenter, retrospective study on 71 patients with combined gastric outlet and biliary obstruction who underwent ERCP through a previously placed enteral stent at 2 tertiary care centers. Outcomes included but were not limited to technical success, clinical success, need for repeat ERCP, adverse events, and survival time.

Results: Overall technical success was achieved in 60 of 71 patients (85%), with technical success of 40 of 46 (87%) in type I obstructions (gastric outlet obstruction above the ampulla), 16 of 21 (76%) in type II obstructions (gastric outlet obstruction at the level of the ampulla), and 4 of 4 (100%) in type III obstructions (gastric outlet obstruction distal to the ampulla). In general, patients who achieved technical success also achieved clinical success. Adverse events occurred in 3 patients (3/71): 2 patients with acute cholangitis and 1 patient with perforation. Average survival time after the procedure was 4.6 months overall.

Conclusions: ERCP performed through enteral stents is safe, with a high technical and clinical success rate, but may be more technically challenging in the setting of type II obstructions. This procedure could be considered first line in the unique setting that a patient requires ERCP through a previously placed enteral stent for malignant gastric outlet and biliary obstruction. (Gastrointest Endosc 2018;87:1499-504.)

Patients with malignant gastric outlet obstruction from pancreatic, ampullary, or duodenal malignancies frequently develop concomitant biliary obstruction and require biliary intervention as their disease progresses.¹ Previously, biliary bypass surgery with or without gastrojejunostomy was the mainstay of treatment.² However, these patients are often poor surgical candidates at the time of presentation because of advanced disease state or comorbidities.

The development of less-invasive endoscopically placed biliary and metal self-expanding metal stents has shifted the paradigm away from traditional surgical treatment. Endoscopy is safer and more cost-effective along with non-inferior outcomes.³ In general, many gastroenterologists advocate placement of a biliary stent prophylactically in patients with malignant gastric outlet obstruction given the likelihood that patients will develop biliary

DISCLOSURE: *The following authors disclosed financial relationships relevant to this publication: A. Siddiqui, D. Loren, T. Kowalski: Consultant for Boston Scientific. A. Siddiqui: Consultant, grant recipient from Medtronic. D. G. Adler: Consultant for Boston Scientific and Merit. All other authors disclosed no financial relationships relevant to this publication.*

Copyright © 2018 by the American Society for Gastrointestinal Endoscopy 0016-5107/\$36.00

<https://doi.org/10.1016/j.gie.2018.01.040>

Received November 15, 2017. Accepted January 28, 2018.

Current affiliations: Gastroenterology and Hepatology, University of Utah School of Medicine, Salt Lake City, Utah, USA (1), Gastroenterology and Hepatology, Jefferson University School of Medicine, Philadelphia, Pennsylvania, USA (2).

Reprint requests: Douglas G. Adler, MD, FACG, AGAF, FASGE, Professor of Medicine, Director of Therapeutic Endoscopy, Director, GI Fellowship Program, Gastroenterology and Hepatology, University of Utah School of Medicine, Huntsman Cancer Center, 30N 1900E 4R118, Salt Lake City, UT 84132.

obstruction at a later time. Indeed, prior studies demonstrated that as many as 60% of patients who receive duodenal stents also ultimately received biliary stents.⁴ In certain circumstances, however, if the biliary stent was not placed before luminal obstruction, then the endoscopist is faced with the unique situation of performing ERCP and attempted biliary stent placement through a previously placed duodenal stent.

The aim of our study was to examine the technical feasibility and clinical success of performing ERCP through duodenal stents to relieve malignant biliary obstructions. To date, this is the largest cohort on this topic known to the literature.

METHODS

We performed a multicenter, retrospective review of patients with combined malignant biliary and duodenal obstruction who underwent ERCP through duodenal stents at the University of Utah Health Science Center in Salt Lake City, Utah and Jefferson University School of Medicine in Philadelphia, Pennsylvania between July 2006 and December 2016. Medical records, endoscopy reports, laboratory results, radiologic studies, telephone records, and other records were reviewed for all patients included in the study.

Inclusion criteria were patients with malignant biliary and duodenal obstruction who underwent an ERCP for attempted biliary decompression performed through duodenal stents. Compiled data included patient demographics, etiology and location of cancer, stent characteristics, need for duodenal self-expanding metal stent strut dilation, type of sedation required, pre- and postprocedure bilirubin levels, and any adverse events.

Outcome data included technical success and clinical success of the procedure and need for any subsequent ERCP after the index biliary stent placement. Technical success was defined as completion of ERCP with successful deployment of a biliary stent. Clinical success was defined as achievement of successful biliary drainage and a decrease in the preprocedure serum bilirubin level to 25% or more within 2 weeks after the procedure. Survival time or time to last documented contact after the intervention was recorded. This study was Institutional Review Board approved at both centers.

RESULTS

Demographics

A total of 71 patients (44 men, 27 women) with malignant biliary obstruction who underwent ERCP through duodenal stents were identified (Table 1). The mean age was 66.87 years (range, 31-92). All patients had underlying malignant disease that had caused gastric outlet and biliary obstruction. The malignant etiologies of

TABLE 1. Patient demographics (n = 71)

Characteristic	Value
Mean age, y	66.87
Male	44 (62)
Female	27 (38)
Tumor	
Pancreatic	36 (51)
Duodenal	15 (21)
Ampullary	5 (7)
Other	15 (21)

Values are n (%) unless otherwise defined.

gastric outlet and biliary obstruction at the time of ERCP were pancreatic cancer (36/71, 51%), primary duodenal cancer (15/71, 21%), ampullary cancer (5/71, 7%), and other (15/71, 21%).

Enteral and biliary stent characteristics

Malignant gastric outlet obstructions were treated using Wallflex enteral stents (Boston Scientific, Natick, Mass) in 70 patients (99%) and 1 Evolution enteral stent (Cook Endoscopy, Winston Salem, NC) in 1 patient (1%). The enteral stents used were 22 × 60 mm (19/71, 45%), 22 × 90 mm (32/71, 45%), and 22 × 120 mm (20/71, 28%). Sixty-eight biliary stents were self-expanding metal stents (96%) and 3 were plastic stents (4%). Sixty-two patients received Wallstent or Wallflex biliary stents (Boston Scientific), 57 of which were 10 × 60 mm in size and 5 were 10 × 80 mm; 6 patients received 10 × 60 mm Alimaxx-B biliary stents (Merit Endotek, South Jordan, Utah).

Type of malignant obstruction

Type of combined biliary and gastric outlet obstruction was documented based on the classification system described by Mutignani et al.⁵ In type 1 patients, the gastric outlet obstruction occurs at the level of the duodenal bulb or upper duodenal genu but without involvement of the major papilla. In type 2 patients, gastric outlet obstruction occurs in the second portion of the duodenum with involvement of the major papilla. In type 3 patients, gastric outlet obstruction occurs in the third portion of the duodenum distal to and without involvement of the major papilla. Of 71 patients, 46 (65%) had type I obstruction, 21 (30%) had type II obstruction, and 4 (6%) had type III obstruction.

Results by type of obstruction

Type I obstruction. Technical success was achieved in 40 of 46 patients (83%) with type I obstruction (Table 2). The 6 patients with unsuccessful biliary stent placement underwent interventional radiology-guided placement of a percutaneous transhepatic biliary drain. Of the 40 patients in whom biliary stent placement was

TABLE 2. Clinical outcome by type of combined obstruction

Type of combined obstruction	Technical success achieved	Rescue procedure performed	Clinical success achieved	Need for reintervention	Average survival time (mo)	Adverse events
Type I (n = 46)	40 (87%)	6/6 percutaneous transhepatic cholangiography	38/40 (95%)	15/46 (33%)	3.1	2/46 (4%) Cholangitis
Type II (n = 21)	16 (76%)	3/5 percutaneous transhepatic cholangiography 2/5 EUS-guided drainage	15/16 (94%)	2/21 (9%)	7.5	0/21 (0%)
Type III (n = 4)	4 (100%)	None	4/4 (100%)	1/4 (25%)	12	1/4 (25%) Perforation

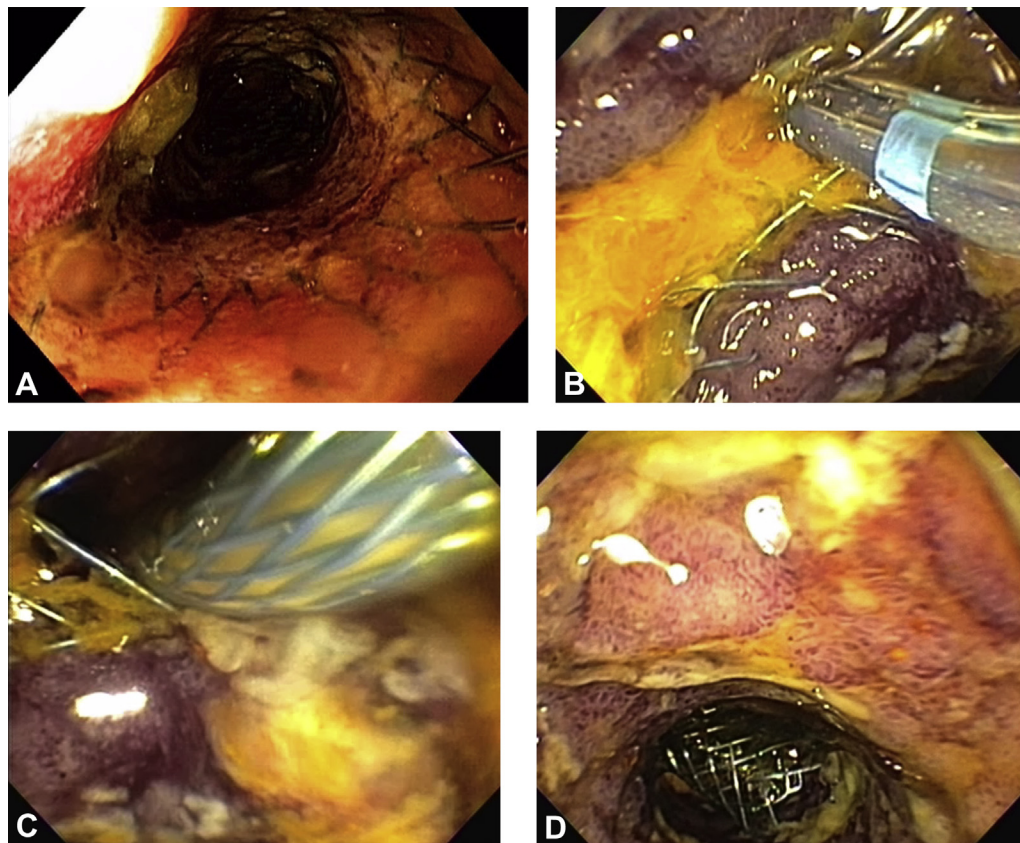


Figure 1. ERCP through a duodenal stent in a patient with type II combined outlet obstruction. **A**, Endoscopic view of a previously placed duodenal stent in a patient with pancreatic adenocarcinoma through an EGD scope. Note that the lumen is much narrower within the stent than would be seen in a normal duodenum. **B**, Cannulation of the same patient as shown in **A** using a duodenoscope through the mesh of the duodenal stent. Note the tissue ingrowth and hyperplasia does not allow the ampulla to be clearly seen; this is typical in these situations. **C**, Passage of a biliary metal stent over a wire through the mesh of the duodenal stent into the bile duct. **D**, Final appearance of the biliary stent after placement through the duodenal stent.

successful, clinical success was achieved in 38 (95%), as evidenced by decrease in average preprocedural bilirubin from 4.4 mg/dL to average of 2.3 mg/dL postprocedurally.

Type II obstruction. Sixteen of 21 patients with type II obstruction achieved technical success (76%). Three patients who did not achieve technical success by ERCP received interventional radiology, whereas 2 underwent

EUS-guided drainage. Fifteen of 16 patients who had technical success also achieved clinical success (94%). The average preprocedure bilirubin for patients with successful ERCP placement was 5.7, which decreased to 4.0 after the procedure (Figs. 1, 2, and 3).

Type III obstruction. All 4 patients with type III obstruction achieved technical success and required no

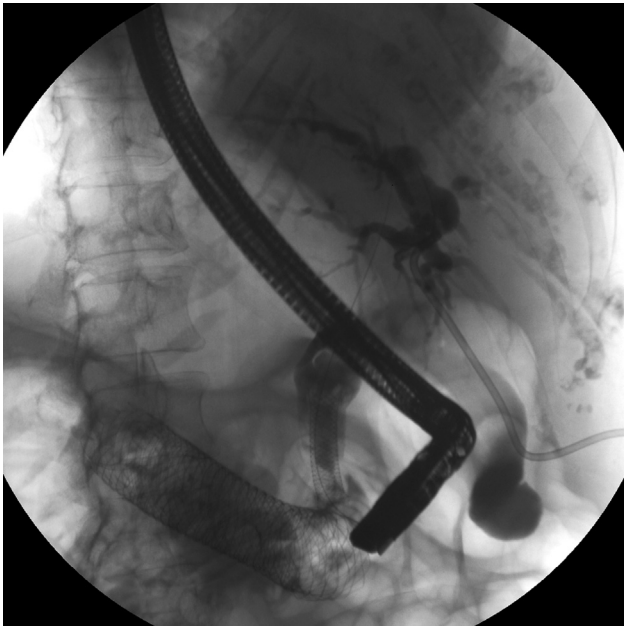

Figure 2. Fluoroscopic view of a biliary self-expanding metal stent after deployment through a duodenal self-expanding metal stent. Note the external biliary drain that was previously placed and does not extend to the duodenal lumen.

alternative intervention (100%). All patients also had clinical success, with a decrease in average bilirubin from 3.13 mg/dL preprocedurally to an average of 1.1 mg/dL postprocedurally.

Survival and etiology of malignancy

The mean survival duration after ERCP and placement of biliary stent in the 71 patients was 4.6 months. Mean survival time for patients who received ERCP through duodenal stents for gastric outlet obstruction in the pylorus, duodenal bulb, second portion of duodenum, and third portion of the duodenum was 2.4 months, 6.2 months, 3 months, and 5.8 months, respectively.

DISCUSSION

Classically, the nonsurgical treatment of malignant biliary obstructions in patients who already have indwelling enteral stents was via percutaneous transhepatic cholangiography because ERCP may be very challenging in these patients.⁶⁻⁸ However, percutaneous transhepatic cholangiography has high rates of drainage occlusion, dislocation, and overall decreased patient quality of life because of drainage causing abdominal wall discomfort. In a study of 385 patients with biliary strictures, Novacek et al⁹ demonstrated that approximately every fifth catheter caused adverse events, requiring additional interventions and in-hospital treatment. For these reasons ERCP with internal drainage is the preferred strategy in these patients.

Challenges with biliary stent placement through enteral stents include achieving an appropriate endoscopic position below the ampulla, limited visualization of the ampulla through the struts of the enteral stent, and technical difficulties involved in cannulating the biliary tree and subsequently placing a stent through the struts of the enteral stent. We found that 2 of the key ingredients in achieving successful cannulation in many patients, especially those with type II combined biliary and duodenal obstruction, were patience and persistence. No specific maneuver was helpful in every case, and approaches were individualized based on visualization, duodenoscope position, and so on.

Previously, self-expanding metal stent manipulation or adjustment to facilitate biliary access has been achieved via various methods, including removal of stent wires with forceps, argon plasma coagulation to melt stent struts, and balloon dilatation of the stent interstices. All these methods carry their own risks and difficulties.^{9,10}

Although a small number of studies have examined simultaneous endoscopic stent placement for patients with duodenal and biliary obstructions, only limited data exist regarding biliary stent placement through previously placed enteral stents that cover the papilla.^{2,8-12} These studies have reported a wide range of technical success rates between 34.2% and 100%. Notably, several of these studies included patients with previously inserted biliary stents or percutaneous transhepatic biliary drainage, which facilitate or “guide” the endoscopist to the major papilla, improving technical success rates.^{5,13} A more recent study by Khashab et al¹² included only patients without prior biliary manipulation and reported successful biliary cannulation in 13 of 38 patients (34.2%). Similarly, our study did not include patients with pre-existing biliary stents and had an overall technical success rate of 85% (60/71).

Prior studies have identified type II obstruction as a risk factor for failure of ERCP when attempting to cannulate through an enteral stent, with type III the least technically difficult and type I having intermediate difficulty; these results make intuitive sense from an anatomic and procedural point of view.^{14,15} For example, in a study of 42 patients Yao et al¹⁴ demonstrated technical success in 88% of patients with type I strictures versus 18.2% with type II strictures and 100% with type III strictures. Our study was consistent with this finding because patients in our study with type II obstructions had the lowest technical success rate of 76%, whereas type III obstructions had the highest technical success rate (100%) and type I obstructions were intermediate, with 83% technical success. The reason for increased technical failure in type II obstruction is the added complexity of localized tumor infiltration further obscuring (or even obliterating) the major papilla, compounding the inherent difficulties previously mentioned.

In general, patients in our study who achieved technical success of biliary stent placement also achieved

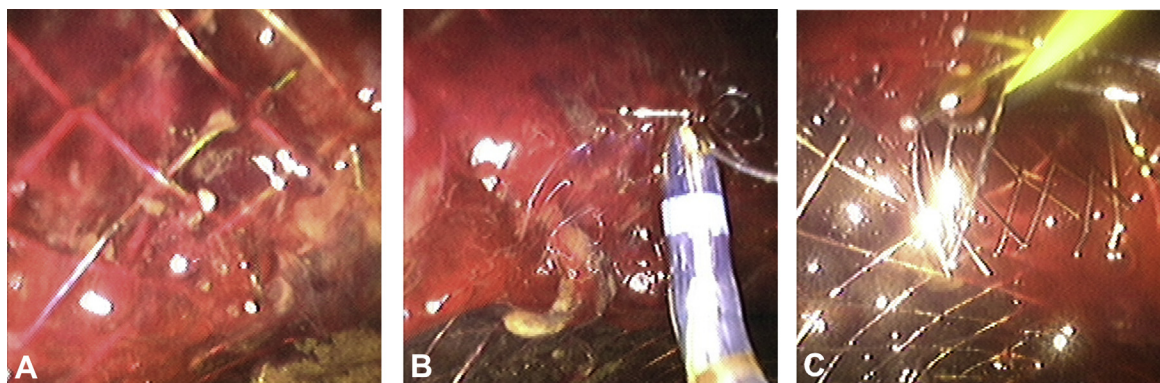


Figure 3. **A**, Endoscopic image of the site of the ampulla viewed through a duodenal stent before cannulation. **B**, Cannulation of the same patient shown in **A**. **C**, Endoscopic view after biliary self-expanding metal stent deployment.

clinical success. By relieving biliary obstruction, patients experience improvement in symptoms associated with jaundice such as nausea, pruritus, and anorexia, which has been shown to be integral to effective palliative care.^{16,17} In our study, 25% of patients (18/71) developed recurrent jaundice and required a repeat ERCP. Interestingly, 15 of 45 patients (33%) with type I obstruction required reintervention, whereas only 2 of 21 patients (9%) with type II obstruction needed reintervention. This suggests that recurrence of jaundice may not correlate with the location of the combined obstruction in relation to the papilla.

The adverse event rate in our study was similar to or lower than reported previously. For example, cholangitis rates are between 2.3% and 8% in the literature for ERCP through duodenal stents.^{5,13} In comparison, for simultaneous duodenal and biliary stent placement the rate of cholangitis is between 7% and 21% in the literature, and the overall incidence of post-ERCP cholangitis in the general population is around 1%.^{3,12,18,19} Our rate of post-ERCP cholangitis was 2 of 71 (3%). Notably, Tierney et al identified stent placement through malignant strictures and presence of jaundice as risk factors for post-ERCP cholangitis, both of which were inherently present in our patient population.^{18,19} Our study had no procedures complicated by post-ERCP pancreatitis or bleeding.

Gastroduodenal and biliary obstruction is known to be a late adverse event from local extension of malignant carcinoma and is an indicator of short survival time because it represents advanced cancer.²⁰ For example, the median survival time in patients with nonresectable periampullary cancer is 6 to 12 months but has been as low as 8 weeks in studies reporting combined obstruction.^{5,13} Our results were similar to the literature with a mean survival of 4.6 months after ERCP through the enteric stent. Notably, in our study type III obstructions had the longest average survival time, but 1 patient with a type III obstruction was still alive at the time of analysis, having survived 72 months after ERCP through the use of a duodenal stent. Further, 1 patient with type II obstruction survived 36 months.

Patients with type II and type III obstructions may present with symptoms earlier than type I obstructions, allowing for earlier palliative or curative intervention. Regardless, performing ERCP through duodenal stents to relieve malignant biliary obstruction does not appear to affect survival time for patients with combined gastroduodenal and biliary obstruction.

Overall, this study demonstrates that performing ERCP through previously placed enteral stents is a safe and effective therapy. One limitation of our study is that we did not have data regarding the time between duodenal stent placement and the development of biliary obstruction because most of these patients had their duodenal stent placed at outside institutions and were sent to our centers for ERCP when jaundice developed. Although more technically challenging in type II obstructions, ERCP through duodenal stent does not appear to have an increased risk of adverse events or decreased survival time when performed by an experienced endoscopist. It should therefore be considered as first-line therapy in patients who develop secondary biliary obstruction.

REFERENCES

1. Adler DG, Baron TH. Endoscopic palliation of malignant gastric outlet obstruction using self-expanding metal stents: experience in 36 patients. *Am J Gastroenterol* 2002;97:72-8.
2. Sohn TA, Lillemoie KD, Cameron JL, et al. Surgical palliation of unresectable periampullary adenocarcinoma in the 1990s. *J Am Coll Surg* 1999;188:658-66; discussion 666-9.
3. Johnsson E, Thune A, Liedman B. Palliation of malignant gastroduodenal obstruction with open surgical bypass or endoscopic stenting: clinical outcome and health economic evaluation. *World J Surg* 2004;28:812-7.
4. Dormann A, Meisner S, Verin N, et al. Self-expanding metal stents for gastroduodenal malignancies: systematic review of their clinical effectiveness. *Endoscopy* 2004;36:543-50.
5. Mutignani M, Tringali A, Shah SG, et al. Combined endoscopic stent insertion in malignant biliary and duodenal obstruction. *Endoscopy* 2007;39:440-7.
6. Moon JH, Choi HJ, Ko BM, et al. Combined endoscopic stent-in-stent placement for malignant biliary and duodenal obstruction by using

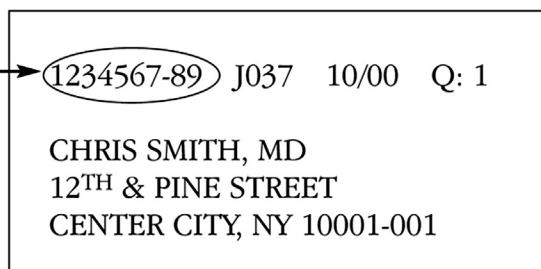
- a new duodenal metal stent (with videos). *Gastrointest Endosc* 2009;70:772-7.
7. Stoker J, Laméris JS. Complications of percutaneously inserted biliary Wallstents. *J Vasc Interv Radiol* 1993;4:767-72.
 8. Oikarinen H, Leinonen S, Karttunen A, et al. Patency and complications of percutaneously inserted metallic stents in malignant biliary obstruction. *J Vasc Interv Radiol* 1999;10:1387-93.
 9. Novacek G, Pötzi R, Kornek G, et al. Endoscopic placement of a biliary expandable metal stent through the mesh wall of a duodenal stent. *Endoscopy* 2003;35:982-3.
 10. Vanbiervliet G, Demarquay JF, Dumas R, et al. Endoscopic insertion of biliary stents in 18 patients with metallic duodenal stents who developed secondary malignant obstructive jaundice. *Gastroenterol Clin Biol* 2004;28:1209-13.
 11. Canena J, Coimbra J, Carvalho D, et al. Endoscopic bilio-duodenal bypass: outcomes of primary and revision efficacy of combined metallic stents in malignant duodenal and biliary obstructions. *Dig Dis Sci* 2014;59:2779-89.
 12. Khashab MA, Valeshabad AK, Leung W, et al. Multicenter experience with performance of ERCP in patients with an indwelling duodenal stent. *Endoscopy* 2014;46:252-5.
 13. Lee JJ, Hyun JJ, Choe JW, et al. Endoscopic biliary stent insertion through specialized duodenal stent for combined malignant biliary and duodenal obstruction facilitated by stent or PTBD guidance. *Scand J Gastroenterol* 2017;52:1258-62.
 14. Yao JF, Zhang L, Wu H. Analysis of high risk factors for endoscopic retrograde cholangiopancreatography biliary metallic stenting after malignant duodenal stricture SEMS implantation. *J Biol Regul Homeost Agents* 2016;30:743-8.
 15. Baron TH. Management of simultaneous biliary and duodenal obstruction: the endoscopic perspective. *Gut Liver* 2010;4(Suppl 1):S50-6.
 16. van den Bosch RP, van der Schelling GP, Klinkenbijn JH, et al. Guidelines for the application of surgery and endoprosthesis in the palliation of obstructive jaundice in advanced cancer of the pancreas. *Ann Surg* 1994;219:18-24.
 17. Kaw M, Singh S, Gagneja H. Clinical outcome of simultaneous self-expandable metal stents for palliation of malignant biliary and duodenal obstruction. *Surg Endosc* 2003;17:457-61.
 18. Cheung KL, Lai EC. Endoscopic stenting for malignant biliary obstruction. *Arch Surg* 1995;130:204-7.
 19. Talukdar R. Complications of ERCP. *Best Pract Res Clin Gastroenterol* 2016;30:793-805.
 20. Lindsay JO, Andreyev HJ, Vlavianos P, et al. Self-expanding metal stents for the palliation of malignant gastroduodenal obstruction in patients unsuitable for surgical bypass. *Aliment Pharmacol Ther* 2004;19:901-5.

Access to ***Gastrointestinal Endoscopy Online*** is reserved for all subscribers!

Full-text access to ***Gastrointestinal Endoscopy Online*** is available for all subscribers. ASGE MEMBER SUBSCRIBERS: To activate your individual online subscription, please visit <http://www.asge.org> and follow the instructions. NON-MEMBER SUBSCRIBERS: To activate your individual online subscription, please visit <http://www.giejournal.org> and follow the prompts to activate your *online access*. To activate your account, you will need your subscriber account/membership number, which you can find on your mailing label (*note*: the number of digits in your subscriber account number varies from 6 to 10 digits). See the example below in which the subscriber account number has been circled:

Sample mailing label

This is your Nonmember subscriber account number →



Personal subscriptions to ***Gastrointestinal Endoscopy Online*** are for individual use only and may not be transferred. Use of ***Gastrointestinal Endoscopy Online*** is subject to agreement to the terms and conditions as indicated online.